

Non-invasive Diagnostic of *Helicobacter pylori* in Stools by Nested-qPCR

MARÍA I. TABORDA¹, GISELA AQUEA¹, YENNY NILO¹, KARLA SALVATIERRA¹,
NICOLÁS LÓPEZ¹, SERGIO LÓPEZ¹, GUSTAVO BRESKY², JUAN A. MADARIAGA^{2,3},
VITTORIO ZAFFIRI², SERGIO HÄBERLE⁴ and GIULIANO BERNAL^{1,2}

¹Laboratory of Molecular and Cellular Biology of Cancer, Department of Biomedical Sciences,
Faculty of Medicine, Universidad Católica del Norte, Coquimbo, Chile

²Department of Biomedical Sciences, Faculty of Medicine, Universidad Católica del Norte, Coquimbo, Chile

³Unit of Pathological Anatomy, Hospital San Pablo, Coquimbo, Chile

⁴Department of Clinical Sciences, Faculty of Medicine, Universidad Católica del Norte, Coquimbo, Chile

Submitted 12 June 2017, revised 01 November 2017, accepted 21 November 2017

Abstract

The aim of this study was to develop a non-invasive diagnostic test for the detection of *Helicobacter pylori* in stool samples from digestive symptomatic patients, using a new protocol of nested-qPCR. A total of 143 patients were invited to participate in the study. A gastric biopsy of each patient was collected for Rapid Urease Testing (RUT) and histology by Giemsa stain. A fecal sample for nested-qPCR analysis was also obtained. DNA was extracted from the fecal samples, and conventional PCR followed by qPCR of the ureC gene of *H. pylori* was carried out. We evaluated the presence of *H. pylori*, in 103 females and 40 males, mean (\pm SD) age of 56.5 ± 14.18 . The sensitivity of RUT to detect the infection was 67.0% (95% C.I.: 57.2–75.8) and specificity was 92.3% (95% C.I.: 76.5–99.1). Histology by Giemsa stain, commonly used as a reference for *H. pylori* detection, showed a sensitivity of 98.6% (95% C.I.: 92.5–100.0) and a specificity of 89.7% (95% C.I.: 72.7–97.8). In contrast, detection of *H. pylori* infection in stools by nested-qPCR showed a sensitivity of 100% (95% C.I.: 94.9–100.0) and a specificity of 83.9% (95% C.I.: 66.3–94.6). Our test, based in nested-qPCR is a better diagnostic alternative than conventional RUT, and is similar to histology by Giemsa stain in the detection of *H. pylori*, by which the test could be used for non-invasive diagnosis in clinical practice.

Key words: *Helicobacter pylori*, molecular diagnostics, nested-qPCR, stools

Introduction

Helicobacter pylori is responsible for gastritis and peptic ulcers; moreover, it is one of the most studied causal agents of gastric cancer (GC) in the last years (Misra *et al.*, 2014), for which in 1994 it was considered as group I carcinogen by the International Agency for Research on Cancer (IARC, 2012). Infection is frequent during childhood and sometimes induces superficial gastritis, which can progress to atrophic gastritis, intestinal metaplasia, dysplasia, and finally GC (Philippe *et al.*, 2016). The gram-negative bacterium adheres and colonizes the gastric mucosa, with the participation of several virulence factors, including cytotoxin-associated gene A antigen (CagA) and vacuolating cytotoxin (VacA), as well as: induced by contact with epithelium (IceA), blood group antigen-binding adhesion (BabA), sialic acid-binding adhesion (SabA), duodenal ulcer-promoting gene (DupA), and outer inflammatory protein (OipA) (Cadamuro, 2014).

In South America, and particularly in Chile, more than 70% of population is positive for *H. pylori* (Coelho and Coelho, 2014), a rate that has been significantly stable during the last 10 years. Different studies have shown a prevalence of infection ranging from 60% to 79%, according to socio-economic, educational and health conditions of the population studied (Ministerio de Salud, 2013). Chile has one of the highest rates of *H. pylori* infection in the world (Ferrecchio *et al.*, 2007; Porras *et al.*, 2014), making it necessary to develop a fast, reliable and non-invasive method to detect the pathogen, before the infected patient develops any gastric pathology, including cancer.

Currently there are two basic genres of tests to detect infection by *H. pylori*: invasive and non-invasive. Invasive tests including culture, histology and the rapid urease test (RUT) (Hunt *et al.*, 2011; Lee *et al.*, 2013; Ministerio de Salud, 2013) are inconvenient, costly, and uncomfortable because a patient is required to go to a hospital or clinic for an endoscopic gastric biopsy. Of

* Corresponding author: G. Bernal, Laboratory of Molecular and Cellular Biology of Cancer, Department of Biomedical Sciences, Faculty of Medicine, Universidad Católica del Norte, Coquimbo, Chile; e-mail: gbernal@ucn.cl

the non-invasive tests, the Urea Breath Test (C^{13} -UBT) and the fecal antigen analysis stand out as the most valuable (Tamadon *et al.*, 2013). C^{13} -UBT is a fast and simple method that detects the presence of *H. pylori* in the gastric mucosa through urease activity of the pathogen (Di Rienzo *et al.*, 2013). Moreover, the test shows high sensitivity and specificity, with sensitivity between 81–100%, and specificity between 80–98% (Honar *et al.*, 2016), but the high initial investment of a isotope ratio mass spectrometer for obtaining results from C^{13} -UBT is not feasible in most public health centers in developing countries. Furthermore, the use of antisecretory drugs or antibiotics can influence the results of the test (Di Rienzo *et al.*, 2013).

Tests that detect *H. pylori* antigens in stool samples show high levels of specificity and sensitivity, similar to those for UBT (Dore *et al.*, 2016), and lately the costs have become more practical for the population. However, the accuracy of these tests decreases when the stools are aqueous because *H. pylori* antigens become diluted. These methods are also not recommended for patients with gastric ulcers (Shimoyama, 2013).

In this context, the aim of the present study was to show and evaluate the efficacy of a new non-invasive diagnostic method based on nested-qPCR, using *ureC* as a gene marker to detect *H. pylori* in stools samples, even in patients with gastric ulcers or watery stools.

Experimental

Materials and Methods

Patients. For this study 143 patients with digestive symptoms were considered: 103 females and 40 males, who were attended to by the Hospital San Pablo, Coquimbo, Chile for a routine gastrointestinal endoscopy. The mean (\pm SD) age of our patients was 56.5 years (\pm 14.18). The inclusion criteria of the patients were as follows: adults over 18 years old, with digestive symptomatology, who had been tested for RUT and histology with Giemsa stain. The Bioethical Committee of the Health Service of Coquimbo, Chile, approved the protocol and patients voluntarily signed their consent.

A patent was requested for this protocol, with the N° 2016–01214 in INAPI (National Institute of Industrial Property, Chile).

Endoscopy and biopsy samples. The endoscopic procedure was performed in Hospital San Pablo, Coquimbo, Chile. Gastric biopsy samples were obtained from each patient for RUT and histology by Giemsa stain analyses, which were processed in the Service of Pathological Anatomy of the Hospital San Pablo according to standard protocols. The same pathologist performed the analysis of all biopsy samples.

Stool samples. Stools by normal evacuation were obtained from each patient before the endoscopic procedure. Each patient provided ~ 5 g of stools placed in a flask containing 3 ml of RNA Later® (Ambion), which were stored in a deep freezer (-80°C) until analysis.

DNA purification and PCR amplification. Approximately 200 mg of each stool sample was used to extract DNA, using QIAamp® Fast DNA Stool Mini Kit (QIAGEN) according to the manufacturer's protocol. Later, 120 ng of the extracted DNA was used to amplify the *H. pylori ureC* gene by nested-qPCR. DNA concentration was quantified by NanoDrop™ One (Thermo Scientific™). In brief, a first amplification with conventional PCR was performed in a Axygen® MaxyGene Thermal Cycler II, incubating 120 ng of DNA with 5 μl Buffer 5x; 1.5 μl MgCl_2 25 mM; 0.5 μl dNTPs 10 mM; 1 μl of each external primer (10 μM each), and 0.2 μl of Platinum Taq® DNA polymerase (5U/ μl) (Invitrogen), in a final volume of 25 μl . Amplification conditions were as follows: a pre-denaturation of 95°C for 5 min, 25 cycles of 95°C for 45 s, 57°C for 45 s and 72°C for 45 s, followed by a final extension at 72°C for 10 min. Posteriorly, 2 μl of a $10\times$ dilution of this first PCR were used for subsequent amplification by qPCR in an Eco Real Time PCR (Illumina®). The qPCR mix contained 5 μl of SYBR Green kit 2x (KAPA SYBR® FAST qPCR) and 0.1 μl of each internal primer (10 μM each), in a final volume of 10 μl . Amplification conditions were: pre-denaturation at 95°C for 5 min, and 30 cycles of 95°C for 10 s and 60°C for 30 s. Sequences of primers are shown in Table I.

Data analysis. Data was analyzed using the Software Eco v4.1 PCR System and the program XLSTAT Version 2.06 to calculate sensitivity, specificity, and positive and negative ratio probability for each of the three techniques: nested-qPCR, RUT and histology by Giemsa stain for detection of *H. pylori* infection in symptomatic digestive patients. Cases for each technique were considered to be *H. pylori* infected according to a com-

Table I
Primers used for qPCR assay.

	Sequence (5'-3') of primers	Amplicon size
External primers <i>ureC</i>	FExt: 5'-AGCTATAAAGTGGGCGAGAG-3' RExt: 5'-ATTGCACCCGTTAGGCTCAT-3'	224 bp
Internal primers <i>ureC</i>	FInt: 5'-GCGTTGGCAGTGCTAAAAGG-3' RInt: 5'-AGCCGTATCTAACACGATCC-3'	127 bp

bined gold standard of RUT/histology, RUT/qPCR or histology/qPCR, as applicable. *P* values < 0.05 were considered significant.

Results

A total of 143 patients with digestive symptoms were evaluated by endoscopy, and the presence of *H. pylori* was evaluated by a novel method of nested-qPCR, and corroborated with RUT and histology by Giemsa stain. We use a combined gold standard for each test evalu-

ated. A patient was considered positive or negative for *H. pylori* when both of tests used as gold standard gave the same result for the infection. Results of the three tests are shown in Table II.

RUT, the standard method used in medical practice to detect the presence of this bacterium, only detected infection in 71/134 patients (53.0%), with a sensitivity of 67.0% (95% C.I.: 57.2 to 75.8) and a specificity of 92.3% (95% C.I.: 76.5% to 99.1); in turn, PPV was 97.3% (95% C.I.: 90.3 to 99.3) and NPV was 42.6% (95% C.I.: 35.7 to 49.8).

Table II
Results of RUT, Histology and Real Time-PCR, for detect *H. pylori* in patients.

Gender	Diagnostic	RUT	Histology	qPCR UreC
Male	High antral lesion benign appearance	+	+	+
Female	Congestive and petechial gastropathy. Duodenal diverticulum	-	+	+
Female	Congestive gastropathy	-	-	+
Male	Petechial gastropathy, hiatal hernia	-	+	+
Male	Gastric ulcer, esophagitis b group, hiatal hernia	+	+	+
Female	Erosive gastropathy, erosive duodenitis, grade I esophagitis	+	+	+
Male	Barrett esophagus esophageal ulcer antral raised lesions	+	+	+
Male	Normal, hiatal hernia	-	+	+
Female	Normal	-	+	+
Female	Erosive gastropathy	+	+	+
Female	Congestive gastropathy	-	+	+
Female	Erosive gastropathy - Esophagitis group b of los angeles	+	+	+
Male	Normal	-	+	+
Female	Congestive gastropathy - Eosinophilic Esophagitis	+	+	+
Male	Normal	-	-	+
Male	Normal	-	+	+
Female	Erosive gastropathy antral multiple polyps fundus	-	+	+
Female	Obs. Celiac Disease	-	+	+
Male	Normal	-	-	-
Male	Antral erosive gastropathy	-	+	-
Female	Erosive Gastropathy	-	+	+
Female	Normal	-	-	-
Female	Normal	+	+	+
Female	Normal	+	+	+
Female	Normal	-	+	+
Female	Hiatal hernia, duodenopathy and congestive gastropathy	+	+	+
Female	Hiatal hernia, duodenopathy and congestive gastropathy	+	+	+
Female	Normal	+	+	+
Male	Hiatal hernia, duodenopathy and congestive gastropathy	+	+	+
Female	Without anormal findings	+	+	+
Female	Normal	+	+	+
Male	Normal	-	+	+
Female	Duodenal ulcer scar (Ulcerous Bulb)	-	+	+
Female	High Antral Lesion	+	+	+
Male	Petechial gastropathy	+	+	+
Female	Normal	+	+	+
Female	Hiatal hernia, erosive esophagitis servera, grade d of los angeles	-	-	-

Table II. Continued

Gender	Diagnostic	RUT	Histo-logy	qPCR UreC
Female	Normal	-	+	+
Female	Congestive gastropathy	+	+	+
Male	Congestive Duodenitis, Antral Erosive Gastritis	+	+	+
Female	Normal	-	-	-
Female	Ulcerous Bulb	-	+	+
Female	Antral Congestive Gastropathy, Nodular	+	+	+
Female	Antral Erosive Gastropathy, High Antral Lesion, Benign aspect	+	+	+
Male	Esophagitis Grade 1	+	+	+
Female	Chronic active gastritis, no evidence of malignant neoplasm is recognized	+	+	+
Male	Esophageal Candidiasis	+	+	+
Female	Congestive gastropathy	+	+	+
Female	Normal	+	+	+
Female	Atrophic Chronic Gastropathy	-	+	+
Female	Esophagitis Grade 1, Chronic Atrophic Gastritis	-	+	+
Female	Petechial gastropathy, Erosive Gastropathy.	+	+	+
Female	Gastritis Congestiva	-	+	+
Male	Normal	+	+	+
Male	Barrett's esophagus, antral ulcer on the anterior aspect of the minor curve	-	+	+
Female	Esophageal submucous lesion	-	-	-
Female	Gatritis congestive	-	-	-
Female	Normal	+	-	-
Female	Normal	+	+	+
Female	Normal	+	+	+
Female	Congestive and deformed bulb, micronodular gastropathy	+	+	+
Female	High Endoscopy Normal	+	-	+
Male	Endoscopy High Normal; Chronic non-specific gastritis	-	+	+
Female	Endoscopy High Normal; Chronic non-specific gastritis	-	+	+
Female	Gastropathy; Moderate non-specific esophagitis, Chronic atrophic gastritis	-	+	+
Female	Chronic gastritis with intestinal metaplasia, suggestive but not conclusive finding of Carcinoma	+	+	+
Female	Possible Congestive and Atrophic Arthropathy, Erosive Duodenopathy; Chronic atrophic gastritis with intestinal metaplasia and indeterminate atypia	-	+	+
Male	Congestive Gastropathy; Chronic Non-Specific Gastritis	-	+	+
Male	Polyps; Chronic Non-specific Gastritis, Tubular adenoma with moderate epithelial dysplasia	+	+	+
Male	Chronic gastropathy, hiatal hernia Esophagitis Moderate to severe erosion; Chronic atrophic gastritis with intestinal metaplasia.	-	-	-
Male	Antral Intestinal Metaplasia; Chronic atrophic gastritis with intestinal metaplasia, Chronic non-specific gastritis	-	+	+
Female	Control Antral Intestinal Metaplasia with important Regression; Chronic gastritis with intestinal metaplasia	+	+	+
Male	Chronic non-specific gastritis	-	-	-
Female	Congestive Duodenopathy; Chronic non-specific gastritis	-	+	+
Male	Moderate to severe erosive esophagitis, gastric ulcers; Chronic atrophic active gastritis, Intense esophagitis, Esophageal candidiasis	-	-	-
Female	Mild erosive esophagitis, erosive gastropathy and congestive duodenitis, increased duodenal papilla volume; Chronic active gastritis	+	+	+
Male	Erosive gastropathy, Antral intestinal metaplasia, Chronic gastritis with focal intestinal metaplasia	-	-	-
Male	Congestive and erosive gastropathy. Possible proliferative lesion (lymphoma or adenocarcinoma). Chronic active gastritis with intestinal metaplasia	+	+	+
Male	Intense gastropathy; Chronic gastritis with intestinal metaplasia and moderate dysplasia	+	+	+

Table II. Continued

Gender	Diagnostic	RUT	Histo-logy	qPCR UreC
Male	Antral intestinal metaplasia, gastric xanthoma, chronic gastritis with intestinal metaplasia	-	+	+
Female	Congestive and petechial gastropathy, sessile polyps; Chronic non-specific gastritis, hyperplastic type polyps	-	-	-
Male	Polyps; Chronic gastritis with intestinal metaplasia	-	+	+
Female	Chronic gastritis	-	-	+
Female	Mild erosive esophagitis; Fibrous polyps; Chronic gastritis with mild atrophy, mild intestinal metaplasia	-	-	-
Female	Active chronic gastritis with focal intestinal metaplasia	-	+	+
Female	Chronic atrophic gastropathy with intestinal metaplasia; Active chronic and atrophic gastritis	+	+	+
Female	Petechial gastropathy, Gastric scars; Active chronic gastritis	+	+	+
Male	Chronic non-specific gastritis	-	-	-
Female	Atrophic gastropathy, Gastric polyps Yamada I; Chronic gastritis	-	-	+
Female	Petechial gastropathy, antral erosions; Chronic gastritis	+	+	+
Male	Esophagitis Grade I; Chronic gastritis	-	-	-
Male	Hiatal hernia, antral congestive gastropathy, esophageal candidiasis; Chronic non-specific gastritis	-	+	-
Female	Gastric ulcer, Active chronic gastropathy with intestinal metaplasia	+	+	+
Female	Mild esophageal stricture; Chronic Gastritis with Intestinal Metaplasia	+	+	+
Female	Normal; Chronic gastritis	-	-	-
Male	Normal; Chronic gastritis Active mild with moderate atrophy	-	+	-
Female	Chronic gastropathy	-	+	+
Female	Chronic gastritis with moderate atrophy and extensive metaplasia, Chronic Active Gastritis with mild Intestinal metaplasia	+	+	+
Female	Gastric Polyps; Mild Chronic Gastritis with Moderate Atrophy and Focal Intestinal Metaplasia, Chronic Active Gastritis with Foveolar Hyperplasia	+	+	+
Female	Chronic gastropathy; Chronic mild gastritis	-	-	-
Male	Grade I esophagitis, chronic gastropathy, erosive duodenitis; Chronic non-specific active gastritis	+	-	-
Male	Chronic atrophic gastritis with mild intestinal metaplasia, moderately differentiated tubular adenocarcinoma	-	-	-
Female	Esophagitis type A of los angeles; Active Chronic Gastritis with mild atrophy, Active Chronic Gastritis with mild atrophy and focal intestinal metaplasia	+	+	+
Female	Atrophic gastropathy; Mild chronic gastritis with mild atrophy	-	-	+
Female	Antral Chronic Gastritis; Active Chronic Gastritis with mild atrophy and mild intestinal metaplasia	+	+	+
Female	Antral atrophic gastropathy, Hiatal hernia, Chronic gastritis with mild atrophy, on-specific chronic gastritis	-	-	-
Female	Ulcerous bulb; Mild chronic gastritis with mild atrophy	-	-	-
Female	Antral superficial gastropathy; Moderate atrophy and intestinal metaplasia, Chronic gastritis with mild inflammatory activity and mild atrophy	+	+	+
Female	Chronic gastropathy; Moderate chronic gastritis, Non-specific chronic gastritis, mild chronic gastritis	+	+	+
Female	Chronic gastropathy; Chronic gastritis with mild inflammatory activity, moderate intestinal metaplasia	-	-	-
Female	Nodular Gastropathy; Chronic active gastritis with moderate inflammatory activity and moderate atrophy.	+	+	+
Male	Antral Erosive Gastropathy; Moderate chronic gastritis with mild atrophy and focal metaplasia; Moderate atrophy and focal intestinal metaplasia	+	+	+
Female	Antral atrophic gastropathy; Moderate chronic gastritis with mild atrophy and moderate intestinal metaplasia	+	+	+
Female	Hiatal Hernia; Mild chronic gastritis, Chronic gastritis with mild inflammatory activity and mild atrophy	+	+	+

Table II. Continued

Gender	Diagnostic	RUT	Histo-logy	qPCR UreC
Female	Antral erosive gastropathy; Chronic gastritis with moderate inflammatory activity, mild intestinal metaplasia and mild atrophy	+	+	+
Female	Chronic atrophic lithiasis gastropathy; Mild chronic gastritis with mild atrophy, Chronic gastritis with moderate atrophy and extensive intestinal metaplasia	-	-	-
Female	Atrophic corpora-antral gastropathy; Active chronic gastritis with moderate atrophy	+	+	+
Female	Esophagitis type C Los angeles, Hiatal Hernia, Non-specific chronic gastritis	-	-	-
Female	Chronic gastritis with mild atrophy and focal intestinal metaplasia	-	+	+
Female	Chronic non-specific gastritis	-	+	+
Female	Nodular gastropathy; Chronic non-specific gastritis, Chronic gastritis with mild atrophy	-	-	-
Male	Chronic gastropathy; Chronic gastritis with mild activity, mild atrophy and focal intestinal metaplasia	+	+	+
Female	Hiatal Hernia; Chronic non-specific gastritis	-	-	-
Female	Petechial gastropathy; Active chronic gastritis with moderate atrophy	+	+	+
Female	Erosive Duodenitis, Duodenal ulcer scar; Chronic non-specific gastritis, Hyperplastic type polyps	+	+	+
Female	Duodenal polyps; Chronic non-specific gastritis	-	+	+
Female	Hiatal hernia, antral gastropathy, chronic gastritis with focal intestinal metaplasia	-	-	-
Female	Antral atrophic gastropathy, antral erosive gastropathy; Chronic non-specific gastritis, mild chronic gastritis	-	+	+
Female	Chronic gastritis with mild atrophy and mild intestinal metaplasia	-	+	+
Female	Petechial Gastropathy, Non-specific chronic gastritis	+	+	+
Female	Chronic gastropathy; Mild non-specific chronic gastritis	+	+	+
Female	Active chronic gastritis with moderate atrophy and moderate intestinal metaplasia; Chronic active gastritis with mild atrophy	+	+	+
Female	Nodular Gastropathy; Chronic active gastritis, chronic non-specific gastritis	+	+	+
Male	Antral superficial gastropathy; Chronic non-specific gastritis	+	+	+
Female	Intestinal metaplasia; Chronic gastritis with mild atrophy and mild intestinal metaplasia	+	+	+
Female	Antral Nodular Gastropathy; Active chronic gastritis with mild atrophy, Non-specific chronic gastritis	+	+	+
Female	Erosive duodenitis, antral superficial gastropathy; Active chronic gastritis with moderate atrophy	+	+	+
Female	Esophagitis type A Los Angeles, erosive gastropathy antral; Active chronic gastritis with mild atrophy	+	+	+
Female	Erosive gastropathy; Mild non-specific chronic gastritis	+	+	+
Female	Normal; Chronic non-specific gastritis	-	-	-
Female	Chronic gastropathy; Chronic active gastropathy with mild atrophy	+	+	+
Female	Chronic gastropathy; Chronic non-specific gastritis	+	+	+
Male	Chronic gastritis with mild atrophy and mild intestinal metaplasia	+	+	+

Histology with Giemsa stain classified 71/101 patients (70.3%) as *H. pylori* positive. Between these patients, 92 had a histologic diagnosis associated with gastrointestinal disease, and the remaining 9 tested normal for histology. Sensitivity for this test was 98.6% (95% C.I.: 92.5 to 100.0) and specificity 89.7% (95% C.I.: 72.7 to 97.8); PPV was 96.0% (95% C.I.: 89.0 to 98.6) and NPV was 96.3% (95% C.I.: 78.7 to 99.5).

Using a nested-qPCR approach, we identified infection of *H. pylori* in 71/102 patients (69.6%), with a sen-

sitivity to detect the presence of the bacterium in stools of 100% (95% C.I.: 94.9–100.0), and specificity of 83.9% (95% C.I.: 66.3 to 94.6); Finally, PPV and NPV were 93.4% (95% C.I.: 86.4 to 96.9) and 100.0% (95% C.I.: 84.0–100.0), respectively. A 2.5% agarose gel electrophoresis stained with ethidium bromide with the amplification of five positive samples for *H. pylori* is showed in Figure 1. Complete results are shown in Tables III–V. Comparative results between sensitivity, specificity, PPV and NPV for each test are shown in Table VI.

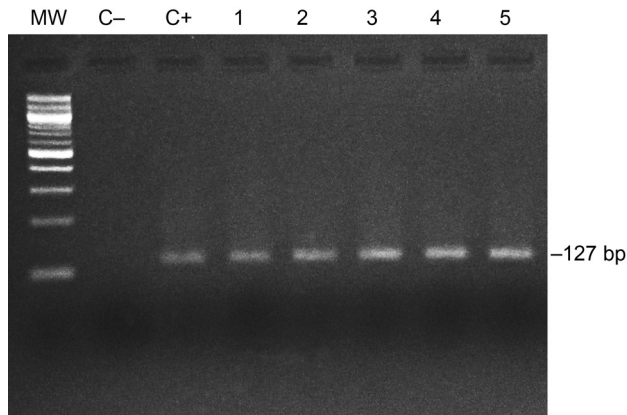


Fig. 1. 2.5% agarose gel electrophoresis stained with ethidium bromide, showing the amplification of five fecal samples positives for *H. pylori*.

C-: Negative control; C+: Positive control (*H. pylori* strain 26695); MW: Molecular weight 100 bp.

Discussion

In this work, we evaluated a combined method of nested-qPCR for detection of infection by *H. pylori* in the stools of 143 gastrointestinal symptomatic patients, and demonstrated that this technique is superior to RUT, the invasive test commonly used in clinical practice today.

One of the pioneering works in this area was conducted in 1994, in which stools of 24 patients diagnosed with *H. pylori* infection were analyzed by PCR. Half of the patients had gastric ulcers at the time of

Table III
Results of RUT vs Histology/qPCR.

	Disease Positive	Disease Negative
RUT +	71	2
RUT -	35	26

$p < 0.0001$

Table IV
Results of histology-Giemsa vs RUT/qPCR.

	Disease Positive	Disease Negative
Histology +	71	3
Histology -	1	26

$p < 0.0001$

Table V
Results of qPCR vs RUT/histology.

	Disease Positive	Disease Negative
qPCR +	71	5
qPCR -	0	26

$p < 0.0001$

endoscopy, while the other 12 had only related dyspepsia. Unfortunately, this study was unable to show that PCR technique is helpful to diagnose infection by the pathogen in the stools. Nonetheless, by inoculating each of the samples with 10^3 bacteria/mg of feces they received a positive result for all samples, a successful advancement in this technique (Mishra *et al.*, 2008). In 1998, a new protocol to detect *H. pylori* by PCR was tested on 100 patients (63 diagnosed with *H. pylori* and 37 healthy for the pathogen). This technique identified 59 infected patients (sensitivity 93.7%), while all uninfected patients tested negative by PCR (specificity 100%) (Aktepe *et al.*, 2011). Moving forward, several studies have shown that this technique may be a useful clinical alternative for *H. pylori* detection in stool samples. In this regard, a study from India in 2008 used nested-PCR of feces to demonstrate the prevalence of infection in the population of that country, finding that of 245 patients evaluated 105 were detected as positive for infection, using a new model for clinical evaluation (Momtaz *et al.*, 2012). Alas, this study did not corroborate their findings with currently accepted techniques, such as RUT or histology. However, this same group later showed that this technique has a high sensitivity, finding 40/52 patients positive for *H. pylori* according by RUT and biopsy, with a sensitivity of 72.5% (Smith *et al.*, 2012).

Another study applied the stool PCR test to 300 patients, 271 of them positive for *H. pylori* by RUT, finding 167/300 positive by PCR (61.6%), using the *ureC* gene as a marker (Uno *et al.*, 2016). Liu and coworkers (2016) evaluated stool samples of 97 digestive symptomatic patients by PCR, with the *ureC* marker and compared their results with UBT. In this work, sensitivity was 42.6% and specificity was 100% (Liu *et al.*, 2016). The authors claim that despite the observed low sensitivity, this technique could be useful for diagnosis in children, especially in health centers that do not have pediatric endoscopes.

In 2014 Patel *et al.* presented a review suggesting that PCR could be superior to other diagnostic tests for detection of *H. pylori* infection, owing to higher sensitivity and specificity, especially with nested and semi-nested approaches (Patel *et al.*, 2014).

In this work, we found that our nested-qPCR is more effective than RUT and similar to histology by

Table VI
Comparative evaluation of RUT, histology and nested qPCR for detection of *H. pylori*.

Parameter	RUT	Histology	qPCR
Sensitivity (%)	67.0%	98.6%	100%
Specificity (%)	92.9%	89.7%	83.9%
PPV (%)	97.3%	96.0%	93.4%
NPV (%)	42.6%	96.3%	100%

Giemsa stain in detecting the presence of infection by *H. pylori* in the patients with digestive symptoms, with a sensitivity of 100% and a specificity of 83.9%. PPV and NPV values were 93.4% (95% C.I.: 86.4 to 96.9) and 100.0% (95% C.I.: 84.0–100.0), respectively.

It is important to note that specificity is close to 84%, as our technique detected five fecal samples as positive for *H. pylori*, which were not detected by RUT or histology. We repeated the test on the samples in question three more times with different portions of the fecal samples, and in all of them the result was positive for *H. pylori*. We hypothesized that our technique had the potential to detect the presence of small quantities of nucleotides from *H. pylori* beyond the limit of detection of the compared techniques.

Moreover, the nested-qPCR method is non-invasive and the patient needs only to send a stool sample to the laboratory, eliminating the need to go to the hospital. Currently RUT, with its low sensitivity, is the standard test in the medical practice. Indeed, in our patients the sensitivity of RUT was only of 67.0%, a result likely associated with ulcer bleeding or the use of proton pump inhibitors, which can give RUT a false negative (Coelho and Coelho, 2014). This is not an issue for PCR based diagnostics.

The proposal that blood could affect the sensitivity of RUT, by the presence of albumin acting as a buffer on the pH indicator of the reaction, is controversial, because other studies report that blood has no effect on the test (Honar *et al.*, 2016).

Our results are encouraging because this technique could soon become a non-invasive method for detection of *H. pylori* in stools, providing the population with an inexpensive and sensitive method to observe presence of the bacterium.

We are waiting for the approval of our patent request N° 2016-01214 for this protocol in INAPI.

Acknowledgments

The authors would like to thank Dr. Héctor Toledo and Dr. Patrio González for their generous gift of *H. pylori* strain 26695, which was used as a control. We thank, moreover, to the Biochemist, Ms. Tracy Wormwood for her kind edition of our manuscript. The studies were funded by CORFO 12IDL2-16202 grant.

Literature

Aktepe O.C., I.H. Ciftçi, B. Safak, I. Uslan and F.H. Dilek. 2011. Five methods for detection of *Helicobacter pylori* in the Turkish population. *World J. Gastroenterol.* 17(47): 5172–5176.

Cadamuro A.C. 2014. *Helicobacter pylori* infection: Host immune response, implications on gene expression and microRNAs. *World J. Gastroenterol.* 20(6): 1424–1437.

Coelho L.G. and M.C. Coelho. 2014. Clinical management of *Helicobacter pylori*: the Latin American perspective. *Dig Dis.* 32(3): 302–309.

Di Rienzo T.A., G. D'Angelo, V. Ojetti, M.C. Campanale, A. Tortora, V. Cesario, G. Zuccalà and F. Franceschi. 2013. 13C-Urea breath test for the diagnosis of *Helicobacter pylori* infection. *Eur. Rev. Med. Pharmacol. Sci.* 17 (Suppl 2): 51–58.

Dore M.P., G.M. Pes, G. Bassotti and P. Usai-Satta. 2016. Dyspepsia: When and how to test for helicobacter pylori infection. *Gastroenterol. Res. Pract.* 2016: 8463614.

Ferreccio C., A. Rollán, P.R. Harris, C. Serrano, A. Gederlini, P. Margozzini, C. Gonzalez, X. Aguilera, A. Venegas and A. Jara. 2007. Gastric cancer is related to early *Helicobacter pylori* infection in a high-prevalence country. *Cancer Epidemiol. Biomarkers. Prev.* 16(4): 662–667.

Honar N., A. Minazadeh, N. Shakibzad, M. Haghghat, F. Saki and H. Javaherizadeh. 2016. Diagnostic accuracy of urea breath test for *Helicobacter pylori* infection in children with dyspepsia in comparison to histopathology. *Arq Gastroenterol.* 53(2): 108–112.

Hunt R.H., S.D. Xiao, F. Megraud, R. Leon-Barua, F. Bazzoli, S. van der Merwe, L.G. Vaz Coelho, M. Fock, S. Fedail, H. Cohen and others. 2011. *Helicobacter pylori* in developing countries. World gastroenterology organisation global guideline. *J. Gastrointest. Liver. Dis.* 20(3): 299–304.

IARC. 2012. Agents Classified by the IARC Monographs, Volumes 1–118. *IARC Monographs* p. 17.

Lee H., T.C. Huang, C.L. Lin, K.Y. Chen, C.K. Wang and D.C. Wu. 2013. Performance of routine *Helicobacter pylori* invasive tests in patients with dyspepsia. *Gastroenterol. Res. Pract.* 2013: 184806.

Liu X., B. He, W.C. Cho, Y. Pan, J. Chen, H. Ying, F. Wang, K. Lin, H. Peng and S. Wang. 2016. A systematic review on the association between the *Helicobacter pylori* vacA i genotype and gastric disease. *FEBS Open Bio.* 6(5): 409–417.

Ministerio de Salud. 2013. Tratamiento de erradicación de *Helicobacter pylori* en el paciente con úlcera péptica. *Serie Guías Clínicas MINSAL.* 2013: 1–44.

Mishra S., V. Singh, G.R. Rao, A.K. Jain, V.K. Dixit, A.K. Gulati and G. Nath. 2008. Detection of *Helicobacter pylori* in stool specimens: comparative evaluation of nested PCR and antigen detection. *J. Infect. Dev. Ctries.* 2(3): 206–210.

Misra V., R. Pandey, S.P. Misra and M. Dwivedi. 2014. *Helicobacter pylori* and gastric cancer: Indian enigma. *World J. Gastroenterol.* 20(6): 1503–1509.

Momtaz H., N. Souod, H. Dabiri and M. Sarshar. 2012. Study of *Helicobacter pylori* genotype status in saliva, dental plaques, stool and gastric biopsy samples. *World J. Gastroenterol.* 18(17): 2105–2111.

Patel S.K., C.B. Pratap, A.K. Jain, A.K. Gulati and G. Nath. 2014. Diagnosis of *Helicobacter pylori*: What should be the gold standard? *World J. Gastroenterol.* 20(36): 12847–12859.

Lehours P. and O. Yilmaz. 2007. Epidemiology of *Helicobacter pylori* Infection. *Helicobacter* Suppl 12: 1–3.

Porras C., J. Nodora, R. Sexton, C. Ferreccio, S. Jimenez, R.L. Dominguez, P. Cook, G. Anderson, D.R. Morgan, L.H. Baker and others. 2014. Epidemiology of *Helicobacter pylori* infection in six Latin American countries (SWOG Trial S0701). *Cancer Causes Control* 24(2): 209–215.

Shimoyama T. 2013. Stool antigen tests for the management of *Helicobacter pylori* infection. *World J. Gastroenterol.* 19(45): 8188–8191.

Smith S.I., M.A. Fowora, O.A. Lesi, E. Agbebaku, P. Odeigah, F.B. Abdulkareem, C.A. Onyekwere, C.A. Agomo and M. Contre-ras. 2012. Application of stool-PCR for the diagnosis of *Helicobacter pylori* from stool in Nigeria- a pilot study. *SpringerPlus* 1(1): 78.

Tamadon M.R., M.S. Far, A. Soleimani, R. Ghorbani, V. Semnani, F. Malek and M. Malek. 2013. Evaluation of noninvasive tests for diagnosis of *Helicobacter pylori* infection in hemodialysis patients. *J. Nephropathol.* 2(4): 249–253.

Uno K., K. Iijima and T. Shimosegawa. 2016. Gastric cancer development after the successful eradication of *Helicobacter pylori*. *World J. Gastrointest. Oncol.* 8(3): 271–281.